

# FBI

## Law Enforcement Bulletin

124513-  
124518

*Lateral Entry*  
*A Move Toward the Future*






### Features



Page 12

- 1 Lateral Entry: A Move Toward the Future** 124513  
By J. Eddie Nix
- 6 Confronting the Terrorist Hostage Taker** 124514  
By G. Dwayne Fuselier and Gary W. Noesner
- 14 Campus Security: The Mule Patrol** 124516  
By James A. Huff
- 20 The Forensic Anthropologist** 124517  
By Robert W. Mann and Douglas H. Ubelaker
- 27 Anticipatory Search Warrants** 124518  
By A. Louis DiPietro

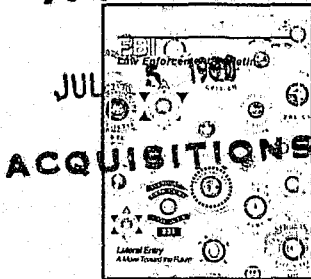


Page 14

### Departments

- 5 Unusual Weapon**
- 12 Police Practices** 124515
- 18 The Bulletin Reports**
- 24 Book Review**
- 25 Major Art Theft**
- 26 Focus**

### NCJRS



The Cover: Successful recruiting in the future may depend on a full-scale lateral entry program. See article p. 1.

United States Department of Justice  
Federal Bureau of Investigation  
Washington, DC 20535

William S. Sessions, Director

Contributors' opinions and statements should not be considered as an endorsement for any policy, program, or service by the FBI.

The Attorney General has determined that the publication of this periodical is necessary in the transaction of the public business required by law of the Department of Justice. Use of funds for printing this periodical has been approved by the Director of the Office of Management and Budget.

Editor—Stephen D. Gladis  
Managing Editor—Kathryn E. Sulewski  
Art Director—John E. Ott  
Assistant Editor—Alice S. Cole  
Production Manager—Andrew DiRosa  
Staff Assistant—Carolyn F. Thompson

The *FBI Law Enforcement Bulletin* (ISSN-0014-5688) is published monthly by the Federal Bureau of Investigation, 10th and Pennsylvania Avenue, N.W., Washington, D.C. 20535. Second-Class postage paid at Washington, D.C., and additional mailing offices. Postmaster: Send address changes to *FBI Law Enforcement Bulletin*, Federal Bureau of Investigation Washington, D.C. 20535.

U.S. Department of Justice  
National Institute of Justice

124513-  
124518

This document has been reproduced exactly as received from the person or organization originating it. Points of view or opinions stated in this document are those of the authors and do not necessarily represent the official position or policies of the National Institute of Justice.

Permission to reproduce this copyrighted material has been granted by  
FBI Law Enforcement Bulletin

to the National Criminal Justice Reference Service (NCJRS).

Further reproduction outside of the NCJRS system requires permission of the copyright owner.

# The Forensic Anthropologist

By  
ROBERT W. MANN, M.A.  
and  
DOUGLAS H. UBELAKER, Ph.D



In recent years, just as the investigation of a crime scene has become more complex and sophisticated, so has the task of the forensic anthropologist. Forensic anthropologists assist medical and legal specialists to identify known or suspected human remains.

The science of forensic anthropology includes archeological excavation; examination of hair, insects, plant materials and footprints; determination of elapsed time since death; facial reproduc-

tion; photographic superimposition; detection of anatomical variants; and analysis of past injury and medical treatment. However, in practice, forensic anthropologists primarily help to identify a decedent based on the available evidence.

For example, when a skeleton found in a wooded area is brought to a morgue or an anthropologist's laboratory for examination, the first step is to determine whether the remains are human, animal, or inorganic material. If human, an anthro-

pologist then attempts to estimate age at death, racial affiliation, sex, and stature of the decedent.

If the skeleton shows evidence of prolonged burial or is accompanied by coffin nails or arrow points, it usually represents an historic or prehistoric burial rather than a recent death. Construction crews frequently unearth such skeletons during road or housing excavations. After combining all of the evidence, the anthropologist determines the skeleton's possible

significance to medical and legal authorities.

Although the primary task of anthropologists is to establish the identity of a decedent, increasingly they provide expert opinion on the type and size of weapon(s) used and the number of blows sustained by victims of violent crime. It should be noted, however, that forensic pathologists or related experts in forensic medicine determine the cause or manner of death, not the forensic anthropologist.

Most anthropologists have advanced degrees in anthropology and have examined hundreds of remains. They are also thoroughly familiar with human anatomy and how it varies in different populations. Some anthropologists may also have experience in police science or medicine, as well as in serology, toxicology, firearms and toolmarks identification, crime scene investigation, handling of evidence, and photography. A limited number of anthropologists deal with footprint analysis and species identification of carrion insects in relation to estimating time elapsed since death.

Perhaps the anthropologist's most valuable skill is familiarity with subtle variations in the human skeleton. Although most adult skeletons have the same number of bones (206), no two skeletons are identical. Therefore, observations of patterns or unique skeletal traits frequently lead to positive identifications. The most frequently used method for identification is to compare before- and after-death dental photoimages. If such photoimages do not exist, or if they are unavailable, then old skeletal injuries or

anatomical skeletal variants revealed in other photoimages may provide the comparative evidence necessary to establish a positive identification.


#### **HYPOTHETICAL EXAMPLE**

Suppose hunters find a partially clothed skeleton lying on the ground in a heavily wooded area with much of its clothing torn and scattered by carnivores. Law enforcement officers are called to the scene, as is the medical examiner or nonphysician coroner. The scene is photographed in detail, and the skeleton is examined and photographed before being removed to the city morgue.

At the morgue, the medical examiner examines the remains for evidence of trauma, such as stab marks in the shirt, blunt trauma to the skull and mandible, and broken

bones. Photoimages and photographs of the body show that no bullets or pellets having been noted. Also, examination of the clothing reveals no wallet or other personal identification.

The medical examiner determines through measurement of the pubic area that the remains are those of a middle-aged adult male. There is no evidence of facial or head hair to aid in determining racial affiliation. From measurements taken at the scene, the examiner roughly estimates the stature. Also, a forensic odontologist is called in to take dental photoimages. Although the decedent has a number of large dental cavities, he shows no restorations or evidence of having seen a dentist. At this point, the medical examiner requests assistance from a forensic anthropologist, who conducts further



*Mr. Mann*



*Dr. Ubelaker*

*The authors are physical anthropologists at the Smithsonian Institution's Department of Anthropology in Washington, D.C.*

study of the remains in the laboratory.

The forensic anthropologist's examination confirms the medical examiner's findings that the individual is a middle-aged male. However, questions remain that the forensic anthropologist must answer, such as:

- What is the individual's racial affiliation?
- What is the individual's age and stature?
- How long has the individual been dead?
- Is there any evidence of trauma or foul play at or near the time of death?
- Are there any distinguishing skeletal traits that may aid in establishing the identity? and
- Is there any indication of post-mortem treatment or alteration of the remains?

### **Racial Affiliation**

The question of racial affiliation is difficult to answer because, although racial classification has some biological components, it is based primarily on social affiliation. Nevertheless, some anatomical details, especially in the face, often suggest the individual's race. In particular, white individuals have narrower faces with high noses and prominent chins. Black individuals have wider nasal openings and subnasal grooves. American Indians and Asians have forward-projecting cheekbones and specialized dental features.

Examination of this skeleton reveals traits consistent with white

racial affiliation. Further examination of the skull produces a few strands of straight blonde hair. Microscopic examination shows the hair to be consistent with that of a white person.

## **“ A forensic anthropologist makes significant contributions to an investigation.”**

### **Age and Stature**

Usually, examination of the pubic bone, sacroiliac joint, amount of dental wear, cranium, arthritic changes in the spine, and microscopic studies of bones and teeth narrows the age estimate given by the anthropologist. After examining the skeleton, these indicators suggest that the man was between 35 and 45 years of age at the time of death.

Estimation of stature can be narrowed by measuring one or more complete long bones, preferably a femur or tibia. If stature estimates are based on incomplete long bones, less confidence can be placed in them. This measurement of the maximum length of the bone can then be plugged into a formula based on race and sex to produce an estimate. In this case the individual's stature was estimated at 5'7" to 5'9" with a mean stature of 5'8".

### **Time Interval Since Death**

Estimating the time interval since death can be extremely dif-

ficult. For the most part, such an estimate is based on the amount and condition of soft tissue, such as muscle, skin, and ligaments present, the preservation of the bones, extent of associated plant root growth, odor, and any carnivore and insect activity. However, many other variables must also be considered, including the temperature at the time of death, penetrating wounds, humidity/aridity, soil acidity, and water retention. The longer the time since death, the more difficult it is to determine the time interval since death. In this hypothetical example, the anthropologist determined that the individual died 6 to 9 months previously, based largely on the condition of the soft tissue and the amount of root growth in the individual's clothing.

### **Evidence of Trauma**

After the dirt and forest debris were removed from the bones using water and a soft brush, a number of faint cuts became visible in the left ribs and the mid-back. The number of discrete cuts in three ribs and in one vertebra suggest that this male was stabbed a minimum of three times. No additional evidence of trauma was noted.

### **Distinguishing Skeletal Traits**

Further examination revealed that the male sustained a fracture above his right eye and upper jaw bone at least several years before death. The individual also had a severely deviated nasal septum and presented evidence of a severe chronic nasal infection. This observation is noteworthy because if he sought medical help for the fractures or sinus condition, photographs or sinus condition, photographs may have been taken that

would provide an excellent opportunity for positive identification.

## POST-EXAMINATION PROCEDURES

After the forensic anthropologist completes the examination, the medical examiner provides all information obtained from the skeleton to the law enforcement officials investigating the case. The information is then entered in the National Crime Information Center (NCIC).

In this hypothetical case, after several months, a search failed to locate a missing person matching this description. Therefore, the medical examiner and the detectives returned to the forensic anthropologist to request that a facial reproduction be attempted.

Two approaches are available to an anthropologist in reconstructing facial appearance during life. First, the anthropologist could work with a composite artist experienced in rendering sketches based on information supplied by eyewitnesses. Or, the anthropologist could call in a specialist in three-dimensional facial reproduction, a technique in which the head is constructed in clay directly over the skull and mandible or over good casts of them. Because of limited funds, and because an experienced composite artist is available on staff, the forensic anthropologist and artist worked together to produce a drawing of the person represented by the skeletal remains. This drawing was then made available to the public via the local media.

Shortly thereafter, two unrelated men who had seen the image on television came forward because

they thought that it might be a relative. Medical and dental records for both individuals could not be located, but facial photographs taken within the last 2 years were available.

Using new techniques of photographic superimposition and comparison, the forensic anthropologist excluded one of the individuals outright. However, frontal photoimages of the second individual taken 3 years before death showed the individual was treated for facial injuries sustained in a motor vehicle accident. The configuration of the frontal sinuses on the photoimages matched exactly the photoimages of the recovered skull, thereby positively identifying the victim.

“  
...a forensic anthropologist is now an integral member of most mass disaster teams.  
”

## VALUE OF FORENSIC ANTHROPOLOGY

A forensic anthropologist makes significant contributions to an investigation. The greatest of these could well be the anthropologist's intensive training and experience in distinguishing between human and nonhuman remains, determining age at death, racial affiliation, sex, stature, elapsed time since death, skeletal trauma, post-mortem damage and alteration of the skeleton, and estab-

lishing positive identification based on skeletal and dental evidence. Such information can be obtained from complete bodies or those partially destroyed by burning, air crashes, intentional mutilation and dismemberment, explosions, or other mass disasters. In fact, a forensic anthropologist is now an integral member of most mass disaster teams.

Through their anthropological training, most forensic anthropologists have knowledge of excavation techniques and mapping that are invaluable in recovering evidence. Consequently, the forensic anthropologist should participate in the investigation of the crime scene and, especially, in the recovery of human skeletal remains.

## CONCLUSION

Many forensic anthropologists offer their services to law enforcement agencies, coroners, and medical examiners. However, if a law enforcement agency does not have access to a forensic anthropologist, experienced experts can be found in many of the larger universities, in anthropology museums throughout the United States, and in some medical examiner's offices. It should be noted, however, that not all physical anthropologists are qualified to practice forensic anthropology. A list of board certified forensic anthropologists can be obtained from the American Academy of Forensic Sciences. Forensic anthropologists have much to contribute to law enforcement and would welcome the opportunity to assist in the successful resolution of an investigation.

**LEB**